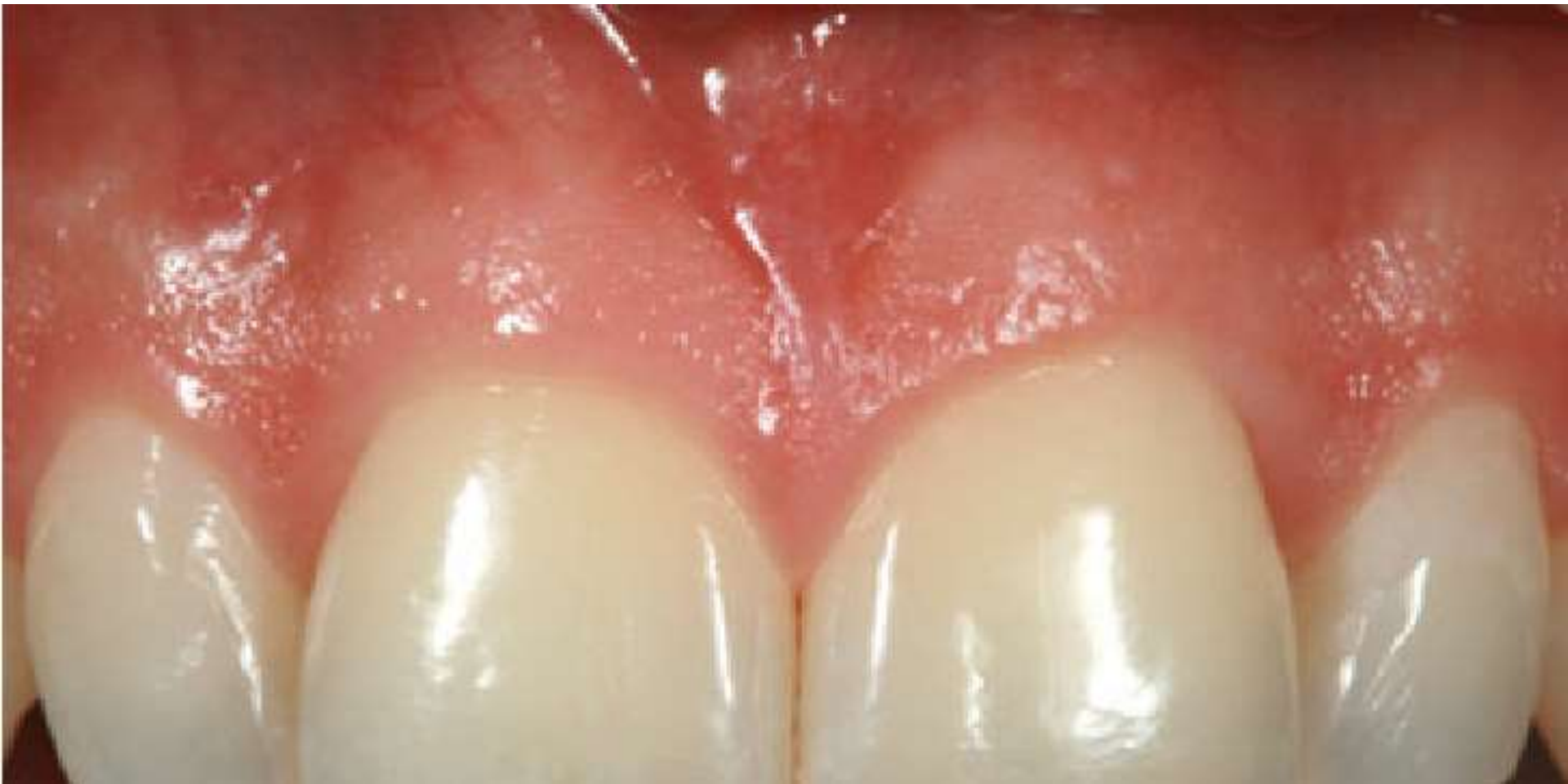

# THE GINGIVA



# INTRODUCTION

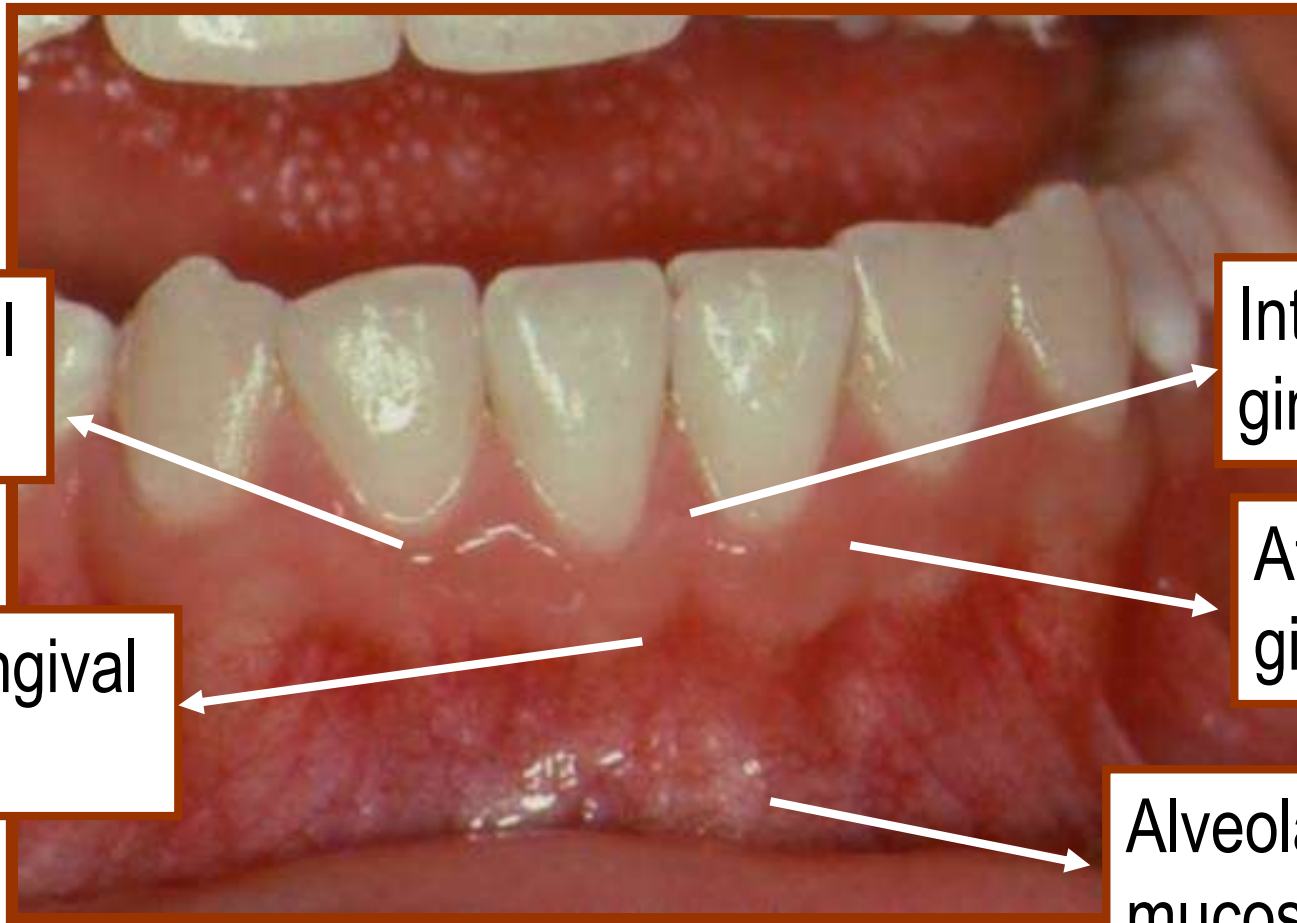
The oral mucosa consists of *three* zones:

- The masticatory mucosa
- Specialized mucosa
- Oral mucous membrane

*“The gingiva is the part of the oral mucosa that covers the alveolar processes of the jaws and surrounds the necks of the teeth.”*

## CLINICAL FEATURES

The gingiva is divided anatomically into...



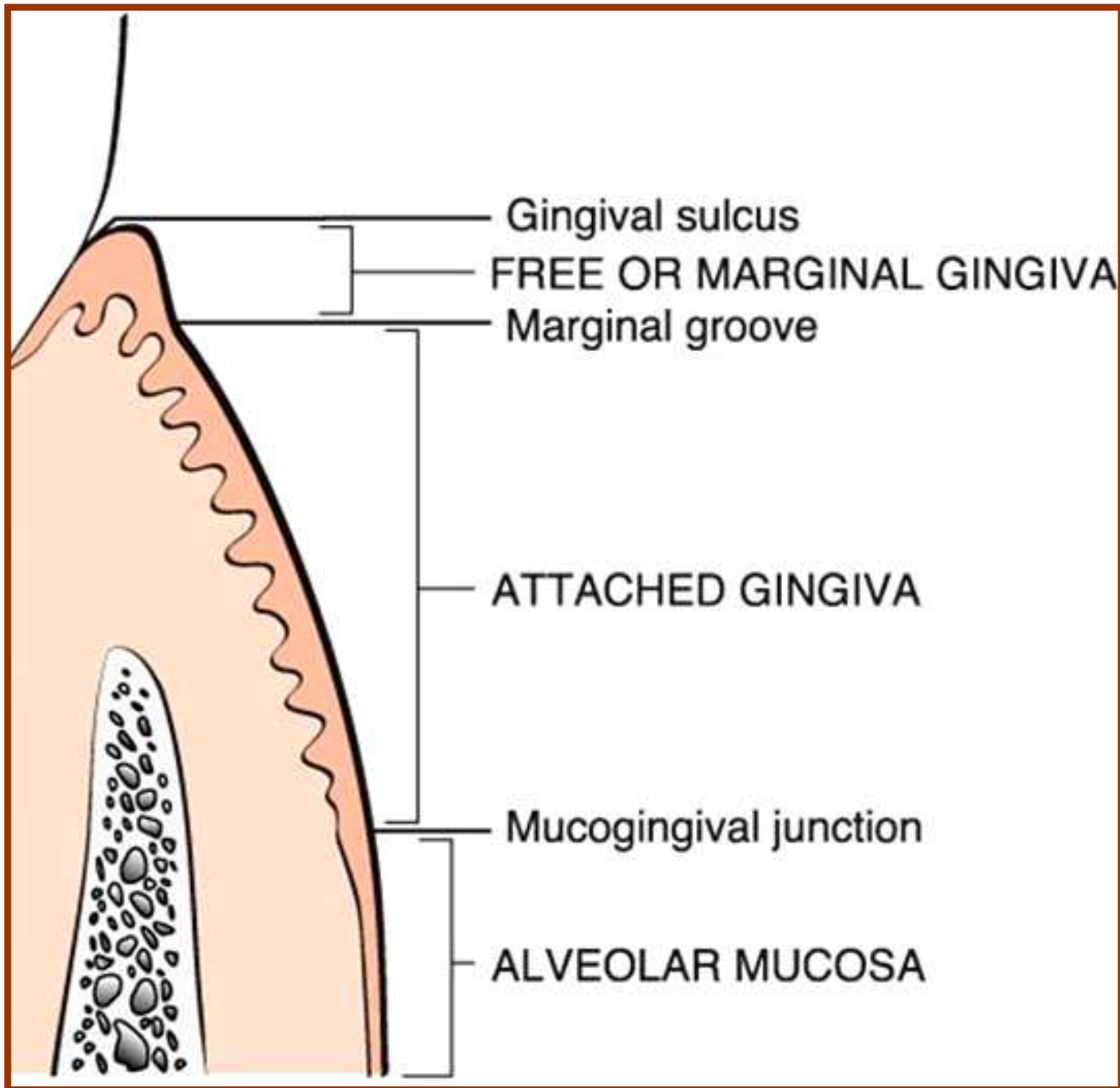
Marginal  
gingiva

Interdental  
gingiva

Mucogingival  
line

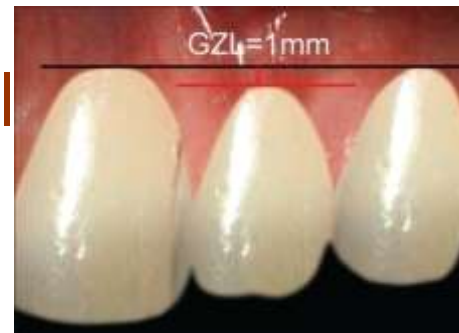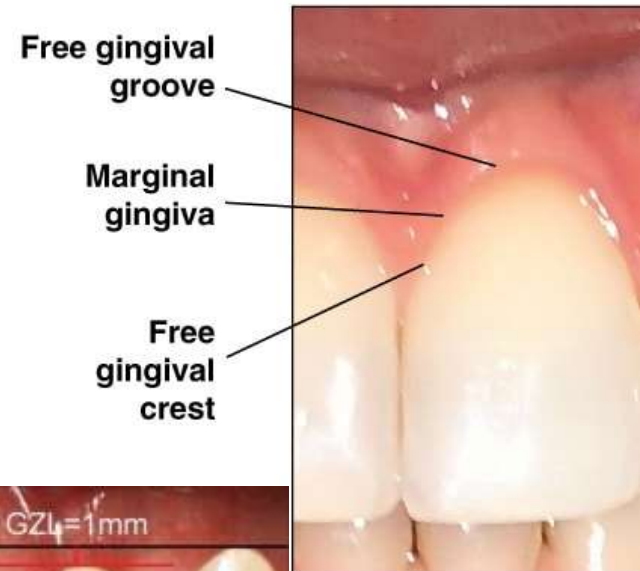Attached  
gingiva

Alveolar  
mucosa



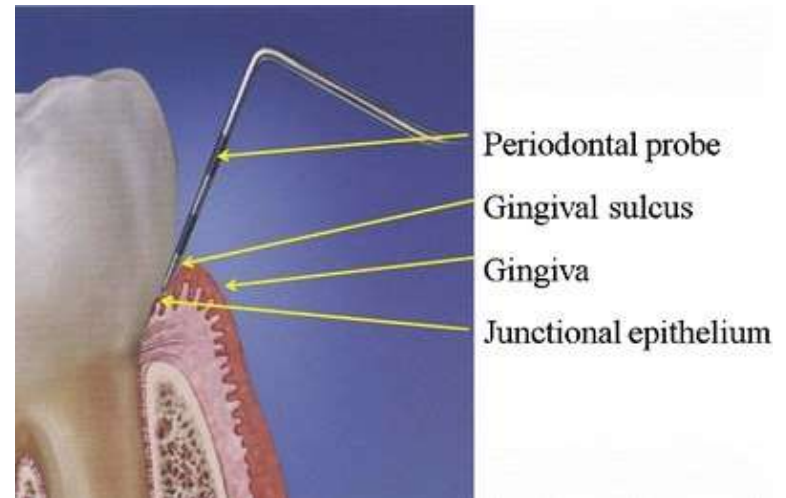
## MARGINAL GINGIVA:

- The marginal , or unattached, or free gingiva is the terminal edge or border of the gingival surrounding the teeth in collar like fashion.
- In about 50% of cases, it is demarcated from the adjacent, attached gingiva by a shallow linear depression, the free gingival groove.
- 1mm wide and forms the soft tissue wall of the gingival sulcus.
- Most apical point of marginal gingival Scallop is gingival zenith.  
0.06-0.96mm



## GINGIVAL SULCUS:

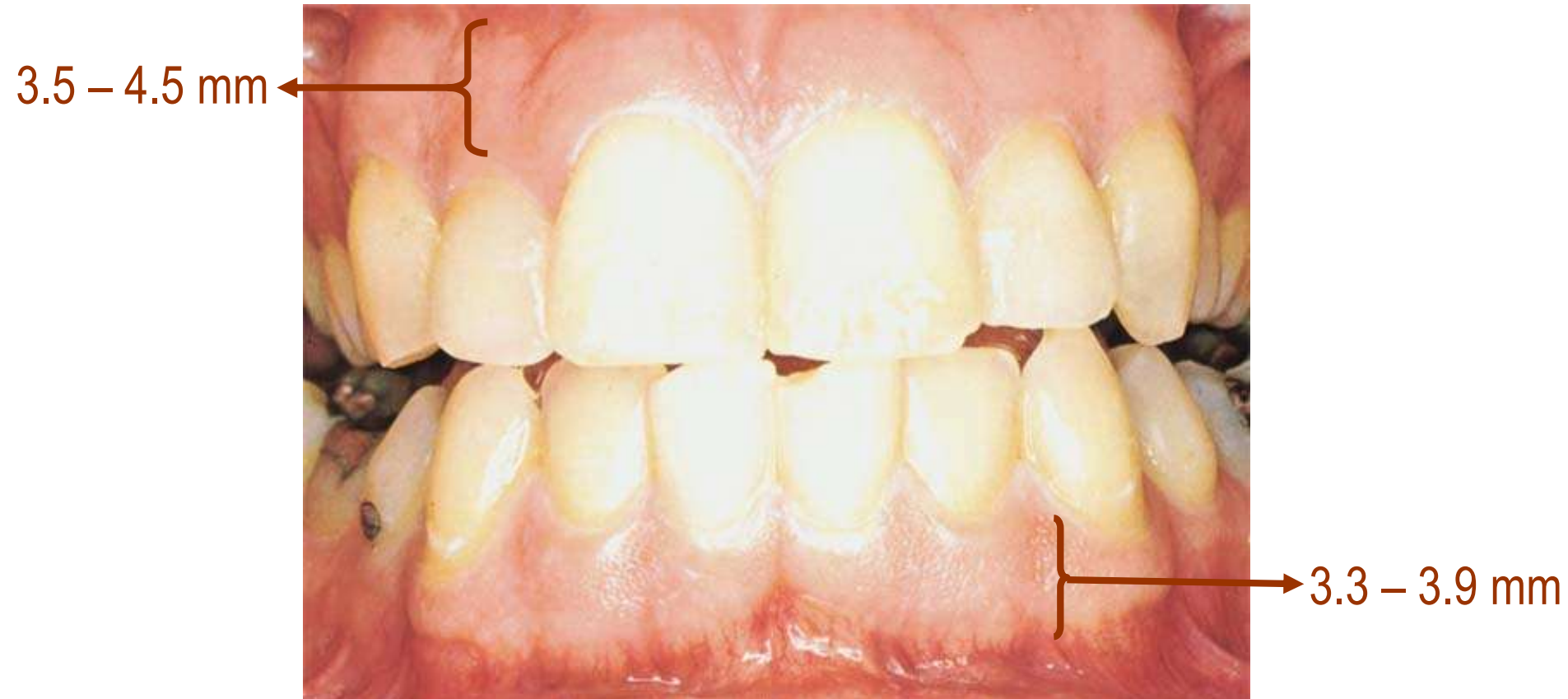- The gingival sulcus is the shallow crevice or space around the tooth bounded by the surface of the tooth on one side and the epithelium lining the free margin of the gingiva on the other.
- It is V shaped and under absolutely normal or ideal conditions, the depth of the gingival sulcus is zero.
- The so-called probing depth of a clinically normal gingival sulcus in humans is 2 to 3mm.



## ***THE ATTACHED GINGIVA***

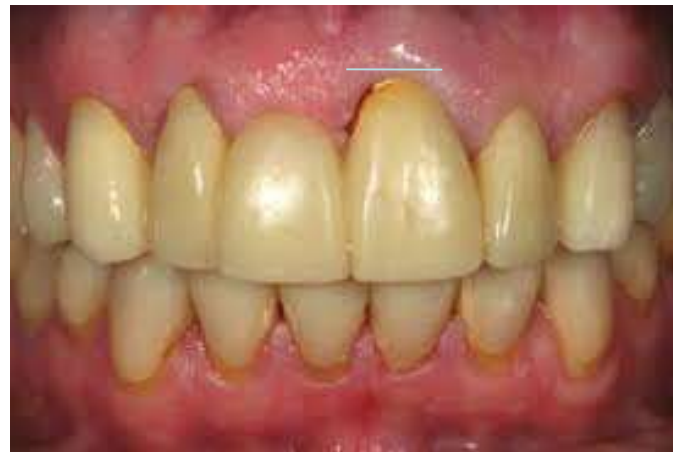- Continuous with the marginal gingiva.
- It is firm, resilient, and tightly bound to the underlying periosteum of alveolar bone.
- The facial aspect of the attached gingiva extends to the relatively loose and movable alveolar mucosa, from which it is demarcated by the mucogingival junction.
- The width of the attached gingiva is another important The width of the attached gingiva on the facial aspects differs in different areas of the mouth .

- It is generally greatest in the incisor region and less in the posterior segments; with the least width in the first premolar area.
- The width of the attached gingiva increases with age.



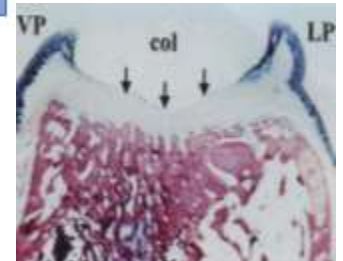
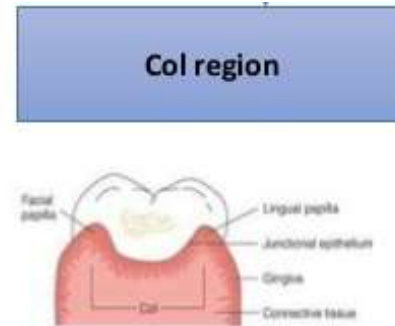
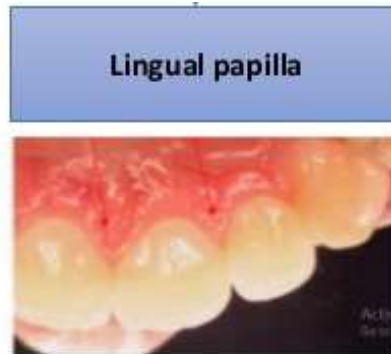
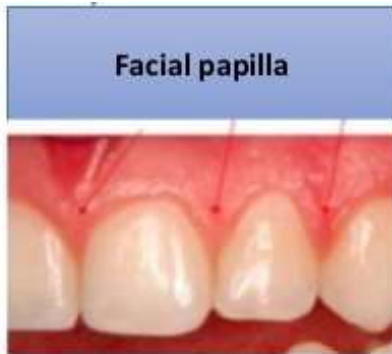

- Because *mucogingival junction* remains stationary throughout adult life, changes in width of attached gingiva are caused by modifications in position of its coronal portion.

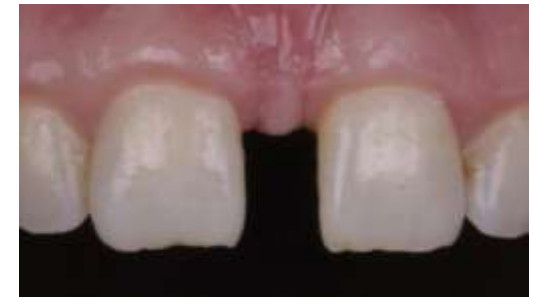

# THE INTERDENTAL GINGIVA:

- The interdental gingiva occupies the gingival embrasure which is the interproximal space beneath the area of tooth contact.
- The interdental gingiva can be pyramidal or have a “col” shape.



- If diastema is present the gingiva is firmly bound over the interdental bone and forms a smooth rounded surface without interdental papillae.



## **MICROSCOPIC FEATURES**


### **GINGIVAL EPITHELIUM**

- **The oral or outer epithelium**
- **Sulcular Epithelium**
- **Junctional epithelium.**

The principal cell type of the gingival epithelium, as well as of other stratified squamous epithelia, is the *keratinocyte*. Other cells found in the epithelium are the clear cells or *nonkeratinocytes*, which include the

- *Langerhans cells,*
- *Merkels cells, and*
- *Melanocytes.*


# GINGIVAL EPITHELIUM: Cell types



**Keratinocytes**



**Melanocyte**



**Langerhans APC cell**

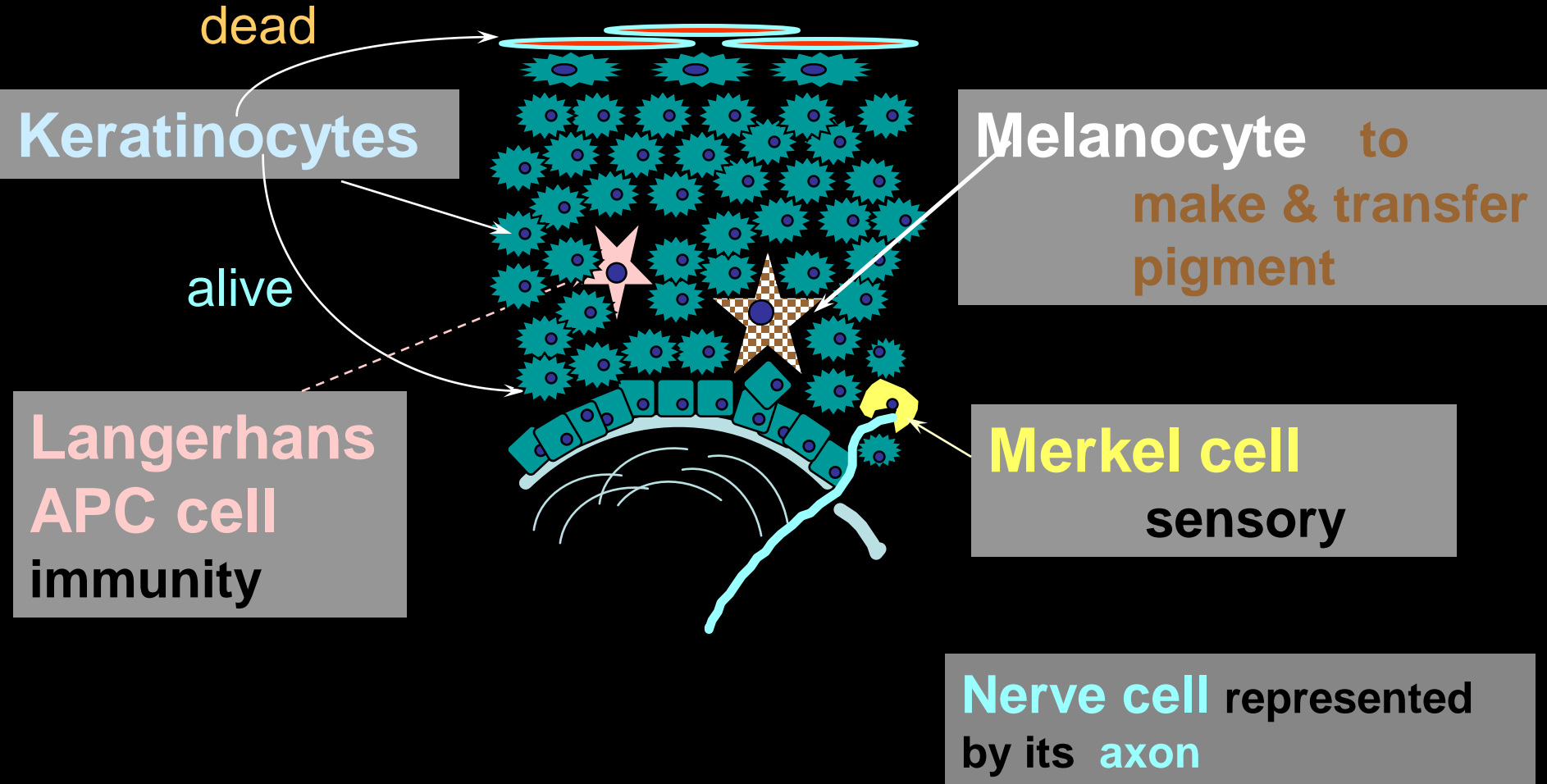


**Merkel cell**



**Nerve cell (axon)**

# GINGIVAL EPITHELIUM: Cell types



*The main function of the gingival epithelium is to protect the deep structures while allowing a selective interchange with the oral environment.*

This is achieved by *proliferation* and *differentiation* of the keratinocyte.

*Proliferation* of keratinocytes takes place by mitosis in the basal layer.

*Differentiation* involves the process of keratinization, which consists of a sequence of biochemical and morphologic events.

A complete keratinization process leads to the production of an **orthokeratinized superficial horny layer** similar to that of the skin with no nuclei in the stratum corneum and a well-defined stratum granulosum.

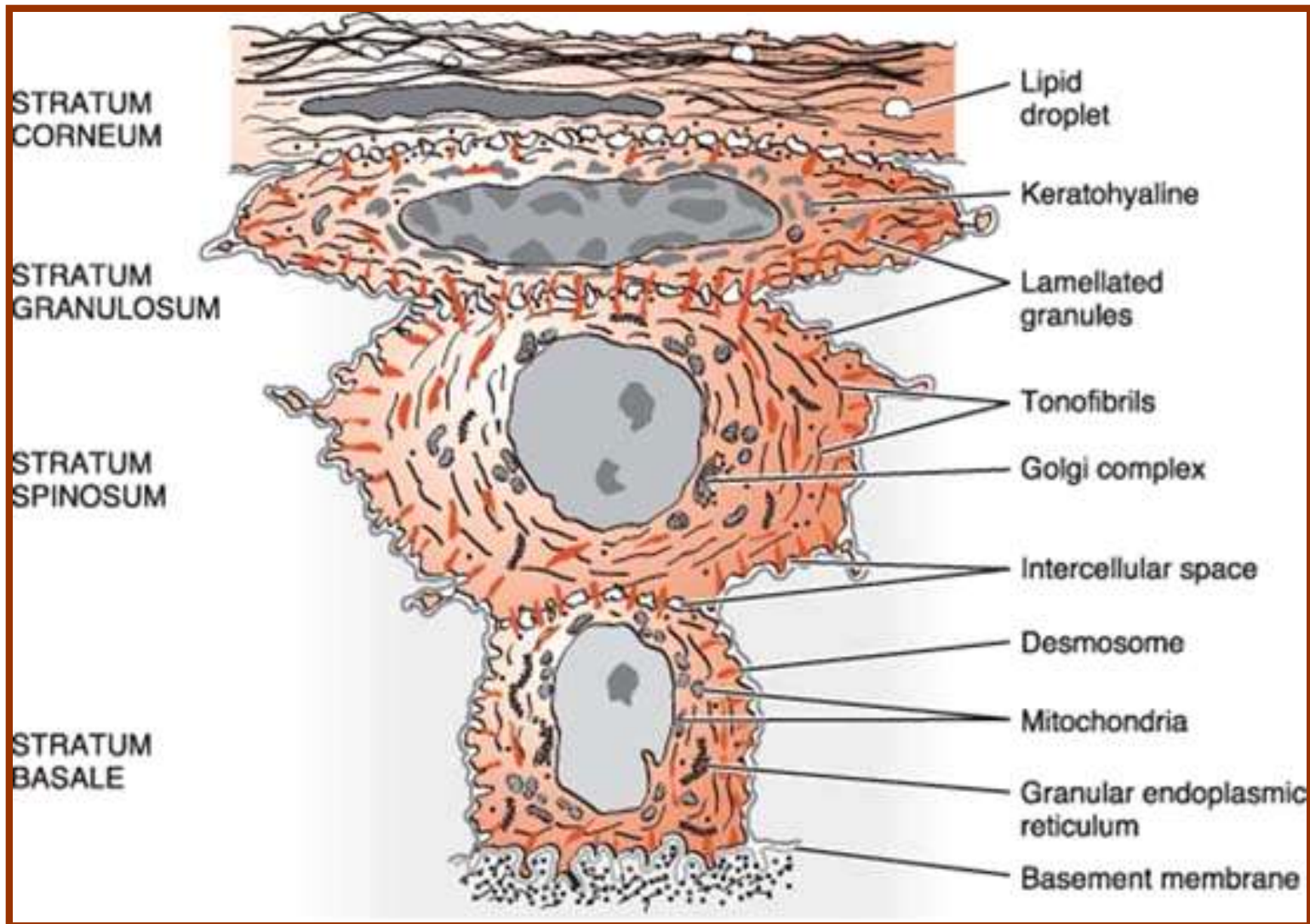
*Melanocytes* are dendritic cells located in the basal and spinous layers of the gingival epithelium. They synthesize melanin in organelles called premelanosomes or melanosomes.



*Langerhans cells* are dendritic cells have an important role in the immune reaction as antigen-presenting cells for lymphocytes.

*Merkel cells* are located in the deeper layers of the epithelium, harbor nerve endings.

# STRUCTURAL AND METABOLIC CHARACTERISTICS OF THE DIFFERENT AREAS OF GINGIVAL EPITHELIUM:



## THE ORAL OR OUTER EPITHELIUM

The oral or outer epithelium covers the crest and outer surface of the Marginal gingiva and the surface of the attached of gingiva.

It is keratized or parakeratinized or presents various combinations of these conditions.

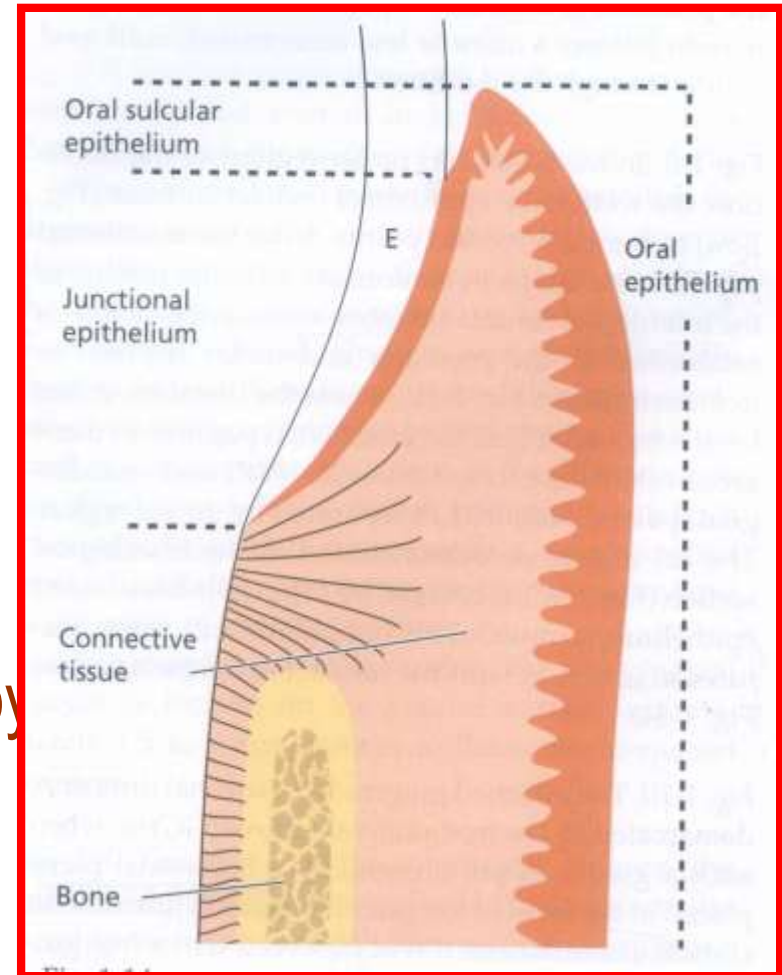
The degree of gingival keratinization diminishes with age and the onset of menopause

## **SULCULAR EPITHELIUM:**

The Sulcular epithelium lines the gingival Sulcus. It is a thin, nonkeratinized stratified squamous epithelium without rete pegs and extends from the limit of the junctional epithelium to the crest of the gingival margin.

# JUNCTIONAL EPITHELIUM

- Stratified squamous nonkeratinizing epithelium.
- It is 3-4 layers thick in early life, but the number of layers increases with age to 10 or even 20 layers.
- The junctional epithelium is formed by the confluence of the oral epithelium and the reduced enamel epithelium during tooth eruption.



# DEVELOPMENT OF THE GINGIVA SULCUS

Tooth erupts in to the oral cavity.  
junctional epithelium and reduced enamel  
epithelium form



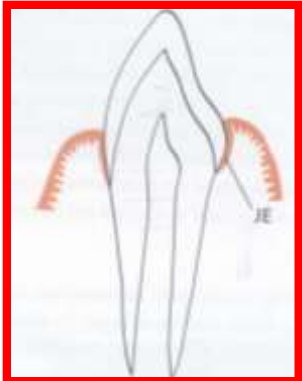
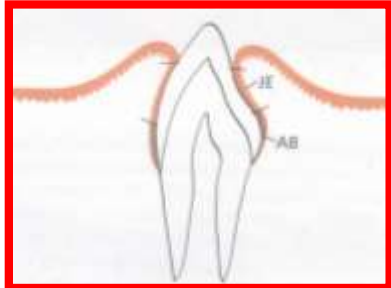
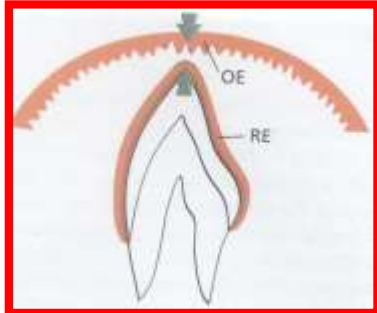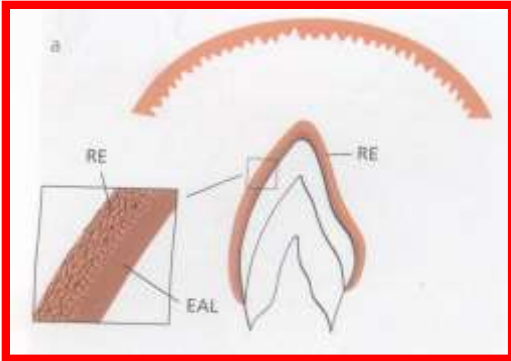
a broad band attached to the tooth surface from  
near the tip of the crown to the cemento enamel  
junction.



'V' shaped space or groove between the tooth and  
gingiva that encircle the newly erupted tip of the  
crown



- In the fully erupted tooth only the junctional  
epithelium persists.



The attachment of the junctional epithelium to the tooth is reinforced by the gingival fibers, which brace the marginal gingiva against the tooth surface. For this reason, the junctional epithelium and the gingival fibers are considered a functional unit, referred to as the **Dentogingival unit**.

## **RENEWAL OF GINGIVAL EPITHELIUM**

The oral epithelium undergoes continuous renewal. Its thickness is maintained by a balance between new cell formation in the basal and spinous layers and shedding of old cells at surface.



## CUTICULAR STRUCTURES ON THE TOOTH

The term cuticle describes a thin, acellular structure with a homogeneous matrix, sometimes enclosed within clearly demarcated, linear borders.

Acquired coatings include, those of exogenous origin, such as saliva, bacteria, calculus, and surface stains coatings of developmental origin are those normally form as path of tooth development. They include the reduced enamel epithelium, coronal cementum, and dental cuticle.

## **GINGIVAL FLUID (SULCULAR FLUID)**

The gingival sulcus contains a fluid that seeps in to it from the gingival connective tissue through the thin Sulcular epithelium.

### **FUNCTIONS OF THE SULCULAR FLUID:**

1. It is the cleanse material from the sulcus
2. Contains plasma proteins that may improve adhesion of the epithelium to the tooth.
3. Possess antimicrobial properties.
4. Exert antibody activity to defend the gingiva.

# THE GINGIVAL CONNECTIVE TISSUE:

The connective tissue of the gingiva is known as the lamina propria and consists of two layers..

- 1) *Papillary Layer* consists of papillary projections between the epithelial rete pegs.
- 2) *Reticular Layer* continuous with the periosteum of the alveolar bone. Connective tissue has cellular and an extracellular compartment composed of fibers and ground substance.

*Connective tissue* fibers three types

- 1) Collagen
- 2) Reticular
- 3) Elastic

The connective tissue of the marginal gingiva is densely collagenous, containing a collagen fiber bundles called the gingival fibers. They consist of *Type I collagen*.

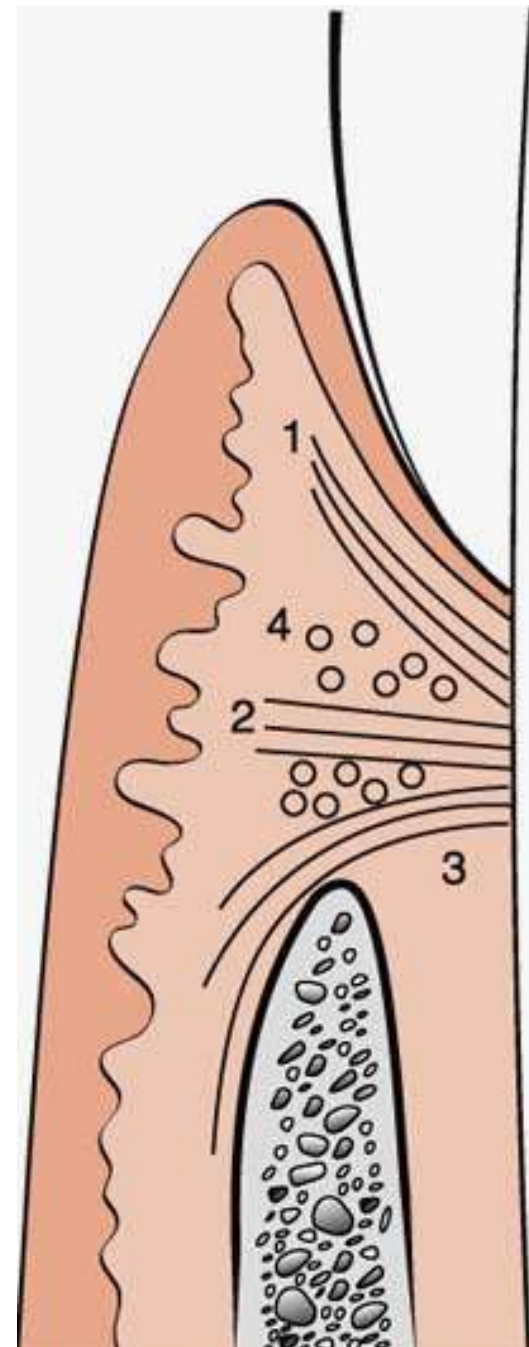
### **FUNCTIONS:**

1. To brace the marginal gingiva firmly against the tooth
2. To provide the rigidity necessary to withstand the forces of mastication without being deflected away from the tooth surface
3. To unite the free marginal gingiva with the cementum of the root and the adjacent attached gingiva.

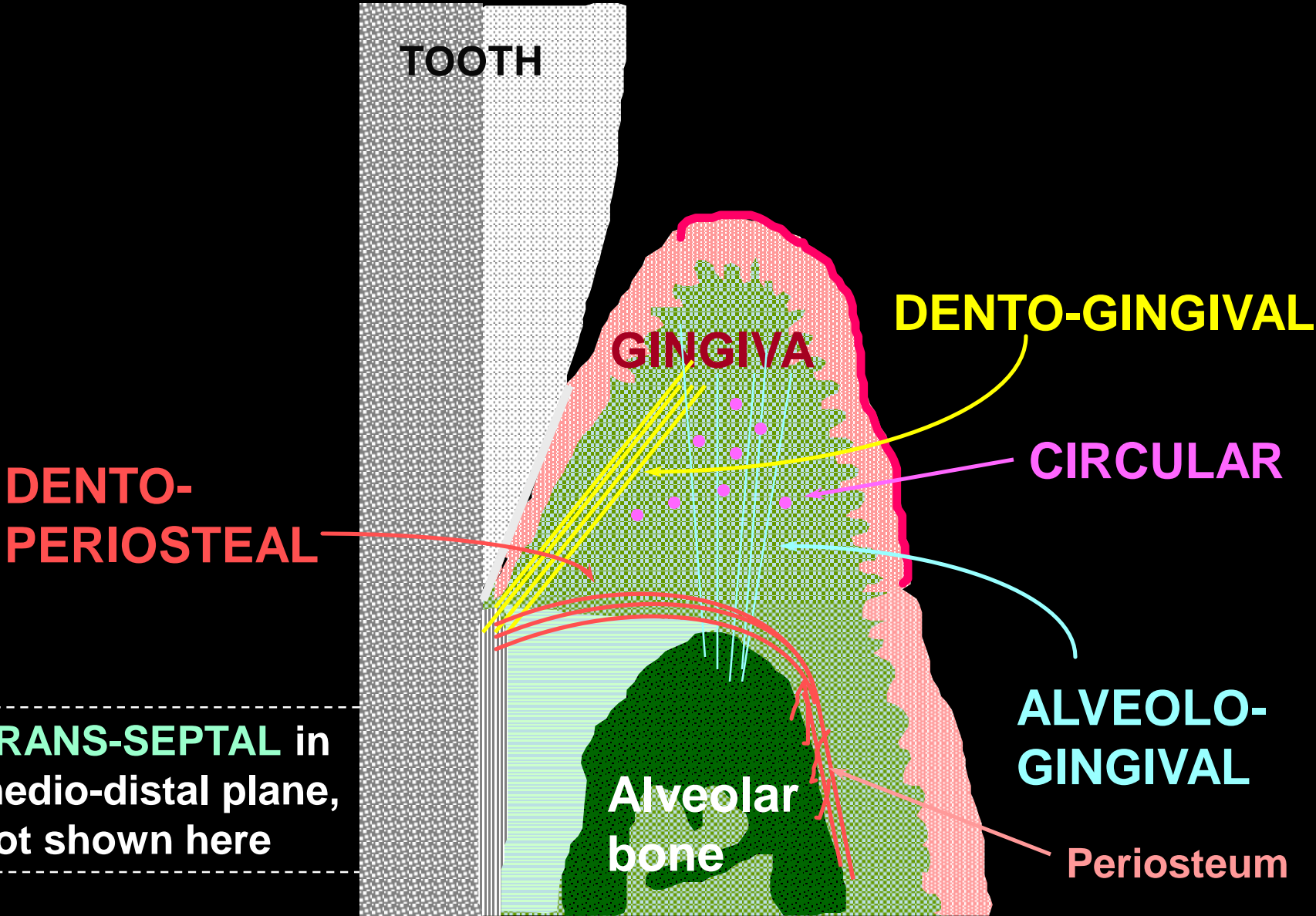
# GINGIVAL FIBERS

Gingival Fibers are arranged in  
*Three Groups*

- Gingivodental Group
- Circular Group
- Transseptal Group



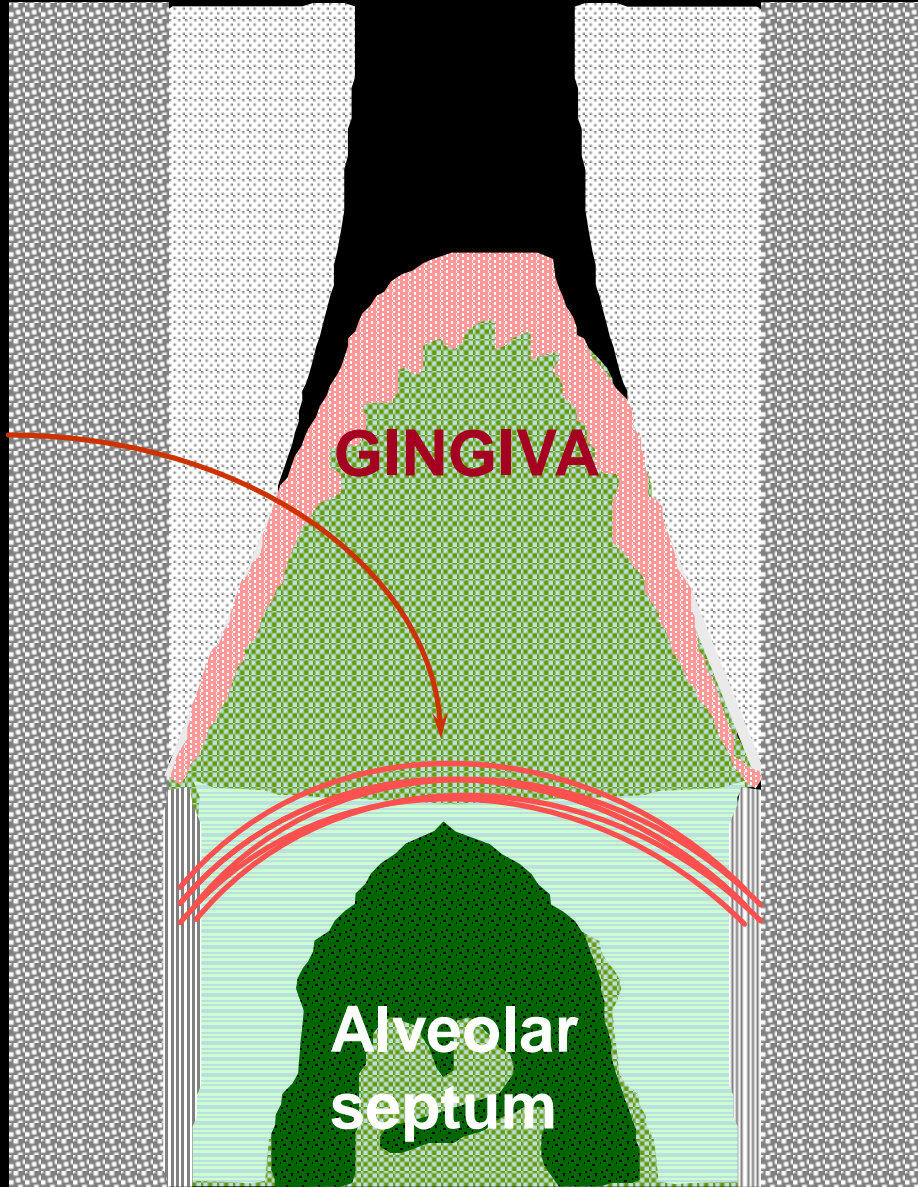
# GINGIVAL FIBER GROUPS



# TRANS-SEPTAL FIBER GROUP

TOOTH

TOOTH



GINGIVA

Alveolar  
septum

**TRANS-SEPTAL**  
in medio-distal  
plane

# GINGIVAL FIBER GROUPS

TOOTH

DENTO-GINGIVAL

ALVEOLO-GINGIVAL

CIRCULAR

DENTO-PERIOSTEAL

TRANS-SEPTAL

DENTO-GINGIVAL

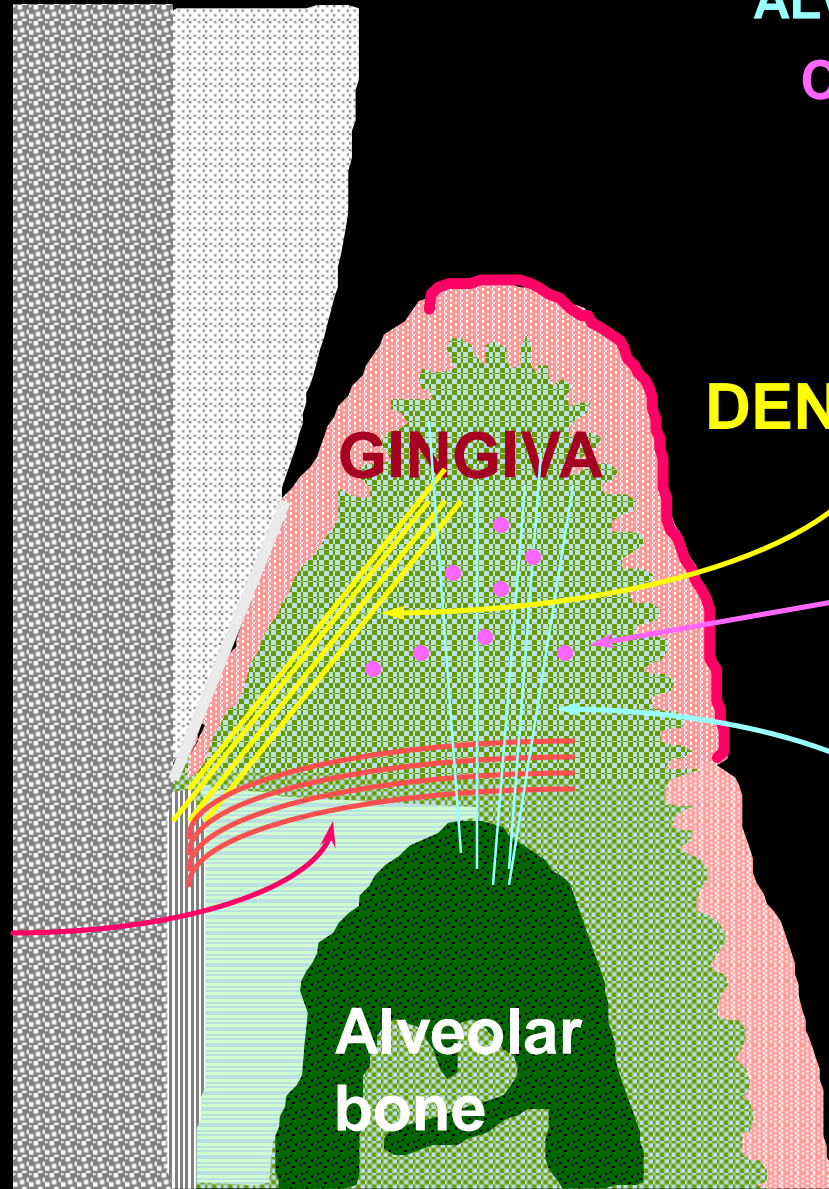
CIRCULAR

ALVEOLO-GINGIVAL

GINGIVA

Alveolar  
bone

**TRANS-SEPTAL**  
if in medio-distal  
plane, not as  
shown here





# BLOOD SUPPLY LYMPHATICS, AND NERVES

- Supraperiosteal arterioles
- Vessels of the periodontal ligament,
- Arterioles arise from crest of interdental septa

The lymphatic drainage of the gingiva brings in the lymphatics of the connective tissue papillae.

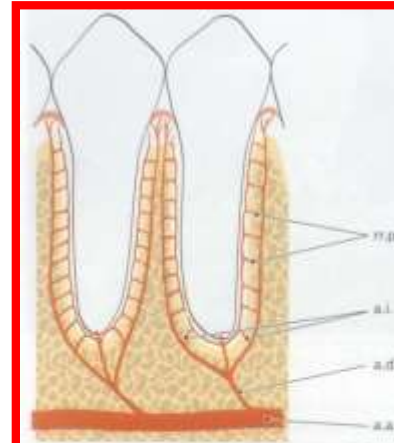


Fig. 1-92

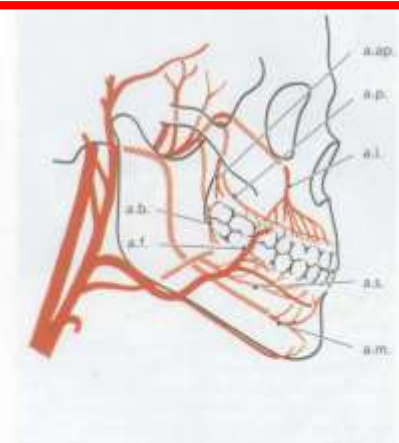
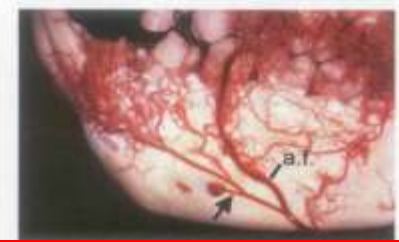
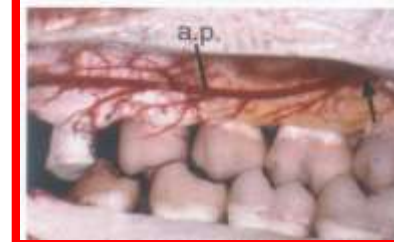
Fig. 1-93



Gingival innervation is derived from fibers arising from nerves in the periodontal in the periodontal ligament and from the labial buccal, and palatal nerves.

The following nerve structures are present:

- *Meissner like corpuscles*
- *Krause-type end bulbs, which are temp receptors*
- *Encapsulated spindles.*

**CORRELATION OF CLINICAL AND MICROSCOPIC  
FEATURES**

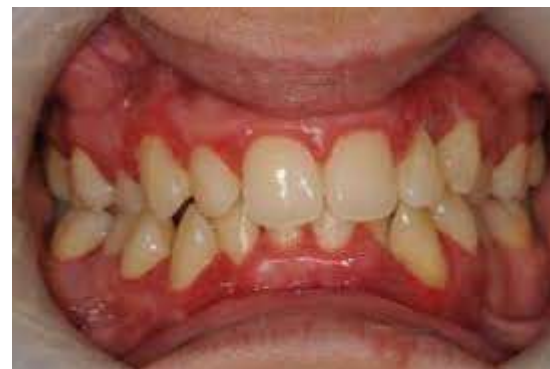
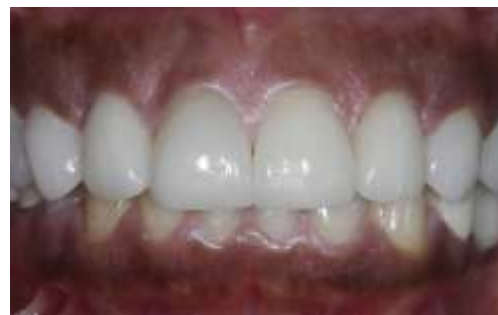
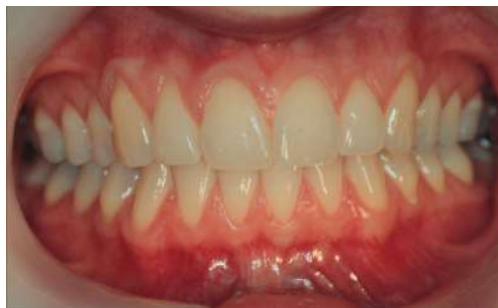TABLE 11-1 Examination of the Gingival Clinical Markers

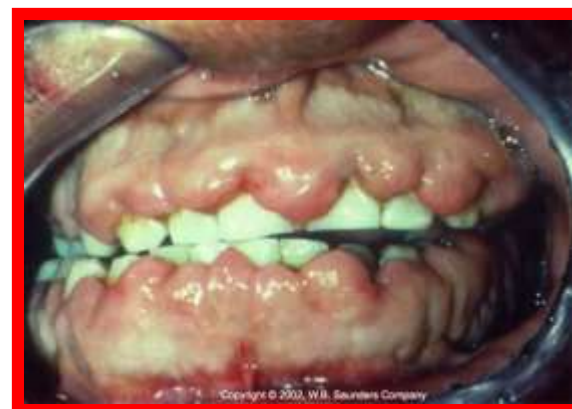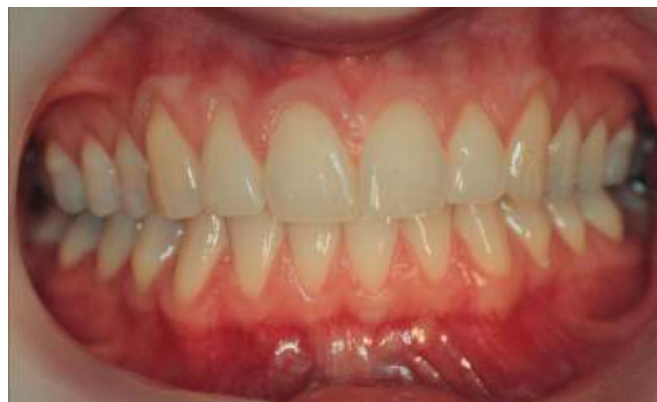	Appearance in Health	Changes in Disease Clinical Appearance	Causes for Changes
Color	Uniformly pale pink or coral pink  Variations in pigmentation related to complexion, race	Acute: bright red	Inflammation capillary dilation increased blood flow
		Chronic: bluish pink, bluish red  pink	Vessels engorged Blood flow sluggish Venous return impaired Anoxemia Increased fibrosis
		Attached gingiva: color change may extend to the mucogingival line	Deepening of pocket, mucogingival involvement
Size	Not enlarged  Fits snugly around the tooth	Enlarged	Edematous: inflammatory fluid cellular exudate vascular engorgement hemorrhage Fibrotic: new collagen fibers
Shape (contour)	Marginal gingiva: knife-edged, flat, follows a curved line about the tooth  Papillae: (1) normal contact: papilla is pointed and pyramidal; fills the interproximal area  (2) space (diastema) between teeth; gingiva is flat or saddle shaped	Marginal gingiva: rounded rolled  Papillae: bulbous flattened blunted cratered	Inflammatory changes: edematous or fibrous  Bulbous with gingival enlargement (see edematous and fibrotic, above)  Cratered in necrotizing ulcerative gingivitis
Consistency	Firm  Attached gingiva firmly bound down	Soft, spongy: dents readily when pressed with probe Associated with red color, smooth shiny surface, loss of stippling, bleeding on probing	Edematous: fluid between cells in connective tissue
		Firm, hard: resists probe pressure Associated with pink color, stippling, bleeding only in depth of pocket	Fibrotic: collagen fibers



# COLOUR



# SIZE



# CONTOUR

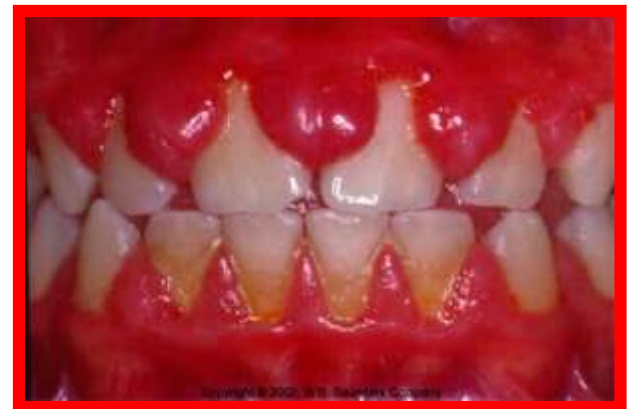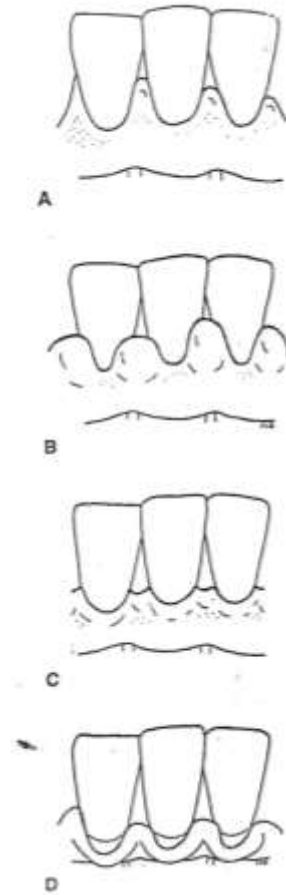

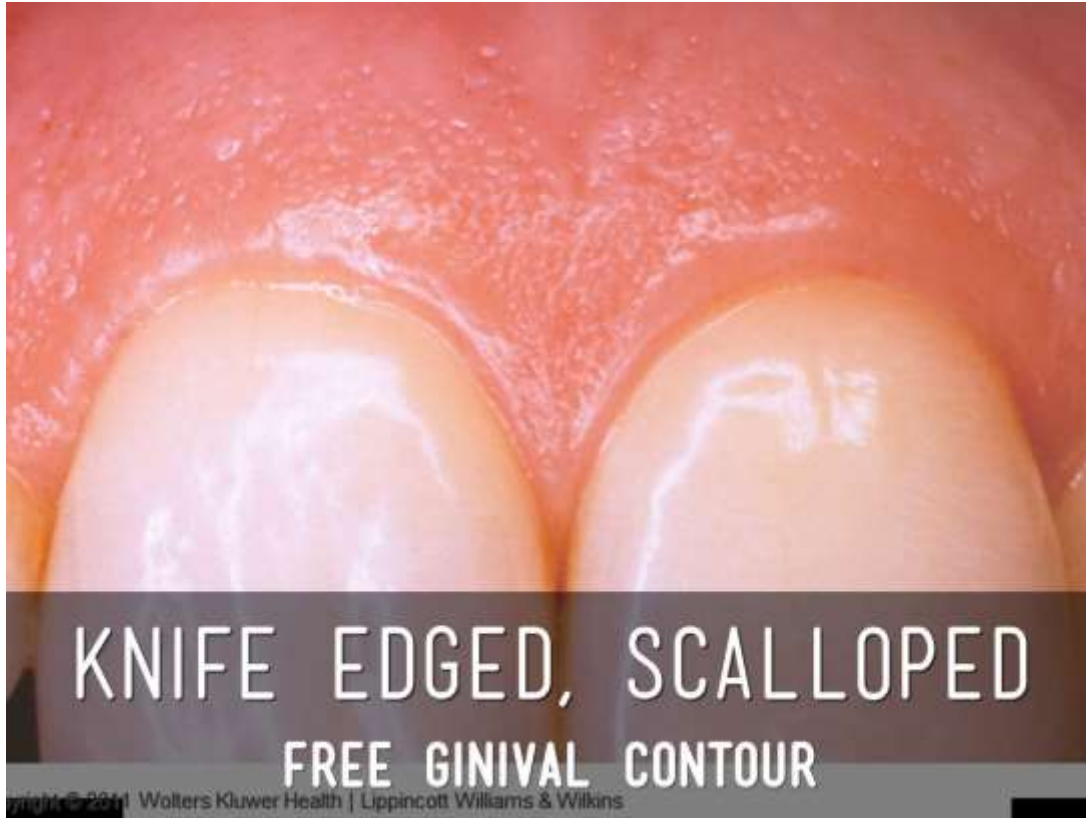
TABLE 11-1 Examination of the Gingival Clinical Markers (Continued)

	Appearance in Health	Changes in Disease Clinical Appearance	Causes for Changes
Surface texture	Free gingiva: smooth  Attached gingiva: stippled	Acute condition: smooth, shiny gingiva  Chronic: hard, firm, with stippling, sometimes heavier than normal	Inflammatory changes in the connective tissue; edema, cellular infiltration  Fibrosis
Position of Gingival Margin	Fully erupted tooth: margin is 1-2 mm above cemento-enamel junction, at or slightly below the enamel contour	Enlarged gingiva: margin is higher on the tooth, above normal, pocket deepened  Recession: margin is more apical; root surface is exposed	Edematous or fibrotic  Junctional epithelium has migrated along the root; gingival margin follows
Position of Junctional Epithelium	During eruption along the enamel surface (Figure 11-7)  Fully erupted tooth: the junctional epithelium is at the cemento-enamel junction	Position determined by use of probe, is on the root surface	Apical migration of the epithelium along the root
Mucogingival Junctions	Make clear demarcation between the pink, stippled, attached gingiva and the darker alveolar mucosa with smooth shiny surface	No attached gingiva: (1) Color changes may extend full height of the gingiva; mucogingival line obliterated (2) Probing reveals that the bottom of the pocket extends into the alveolar mucosa (3) Frenal pull may displace the gingival margin from the tooth	Apical migration of the junctional epithelium Attached gingiva decreases with pocket deepening Inflammation extends into alveolar mucosa
Bleeding	No spontaneous bleeding or upon probing	Spontaneous bleeding Bleeding on probing: bleeding near margin in acute condition; bleeding deep in pocket in chronic condition	Degeneration of the sulcular epithelium with the formation of pocket epithelium Blood vessels engorged Tissue edematous
Exudate	No exudate on pressure	White fluid, pus, visible on digital pressure Amount not related to pocket depth	Inflammation in the connective tissue Excessive accumulation of white blood cells with serum and tissue makes up the exudate (pus)



# SURFACE TEXTURE

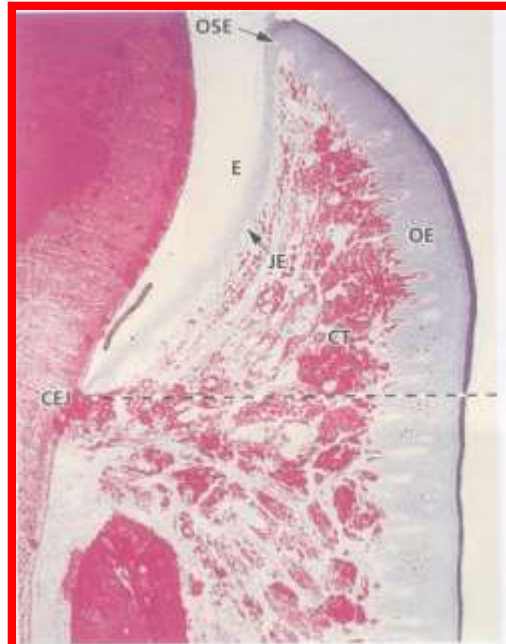
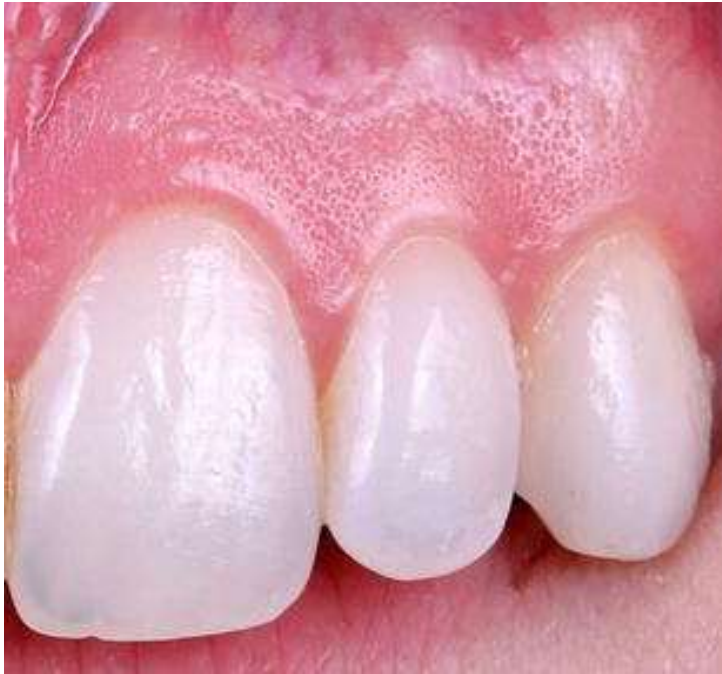
Fig. 1-14b.

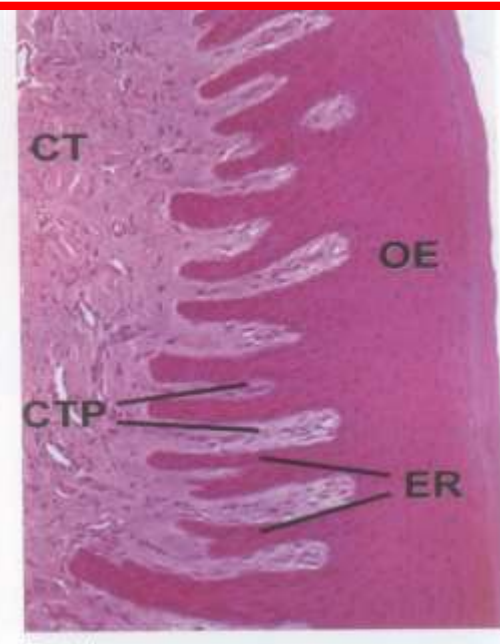
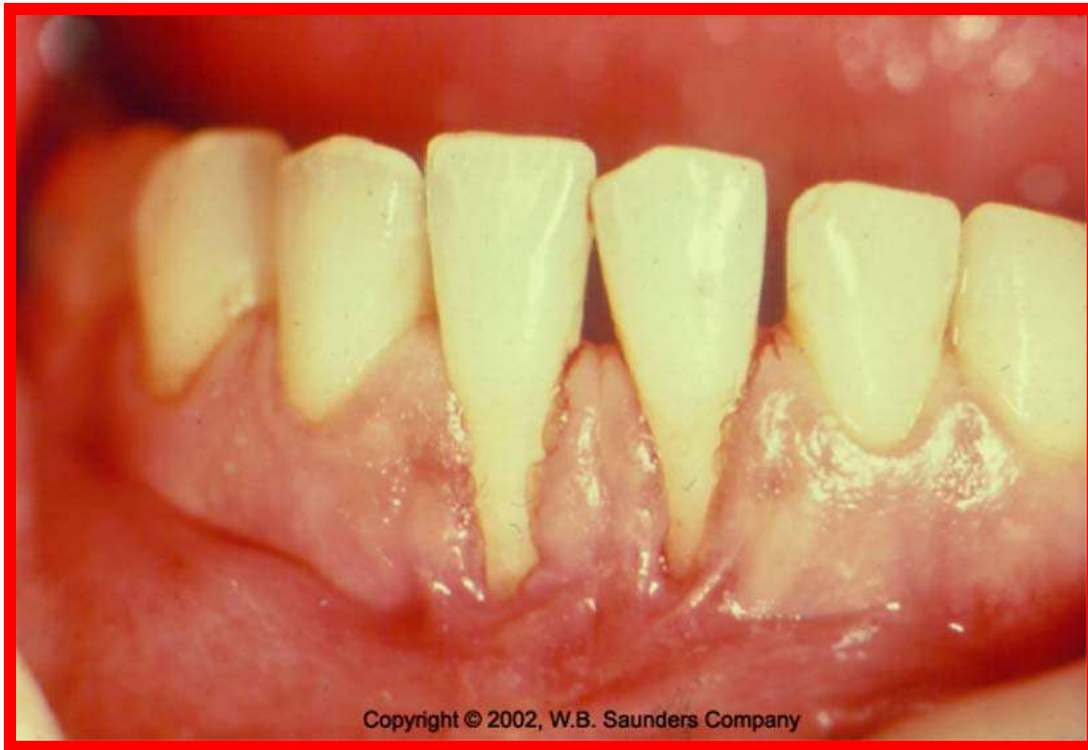


Fig. 1-14c.



Adaptive specialisation or reinforcement for function

# POSITION



Copyright © 2002, W.B. Saunders Company

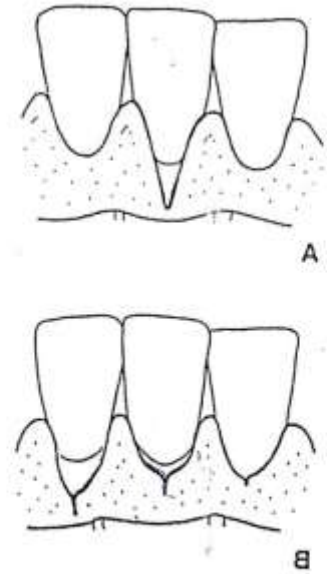


FIGURE 11-11 Gingival Clefts. (A) V-shaped Stillman's cleft. (B) Slit-like Stillman's clefts of varying degrees of severity in relation to the mucogingival junction.

## ***POSITION***

The position of the gingiva refers to the level at which the gingival margin is attached to the tooth.

## ***CONTINUOUS TOOTH ERUPTION***

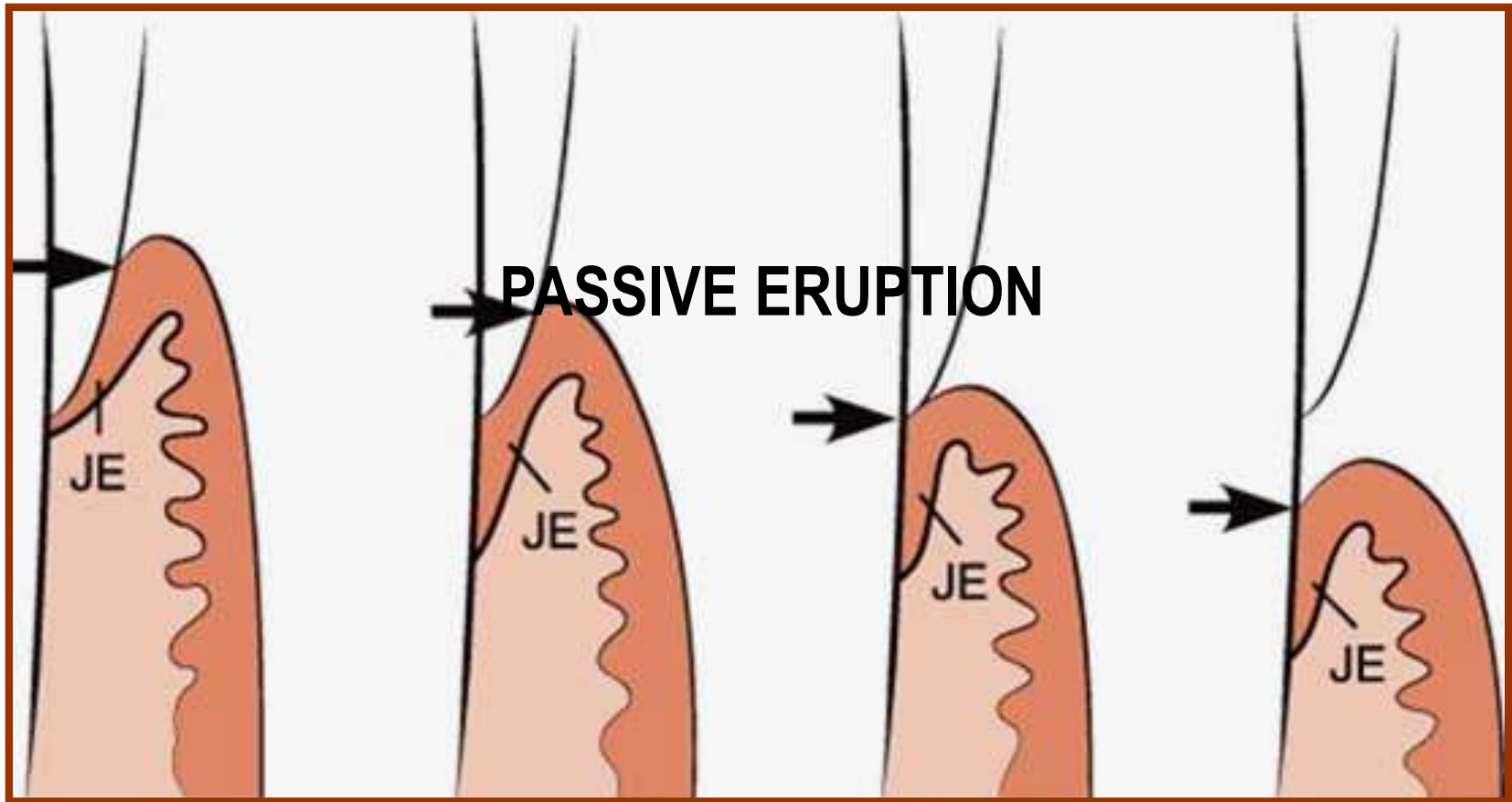
It consists of an active and passive phase.

## ***ACTIVE ERUPTION***

Active eruption is the movement of the teeth in the direction of the occlusal plane.

## PASSIVE ERUPTION

Passive eruption is the exposure of the teeth by apical migration of the gingiva.



Passive eruption is divided into four stages, this was originally thought to be a normal physiologic process, it is now considered a pathologic process.

**Stage 1:** The teeth reach the line of occlusion. The junctional epithelium and base of the gingival sulcus are on the enamel.

**Stage 2 :** The junctional epithelium proliferates so that part on the cementum and part is on the enamel. The base of the sulcus is still on the enamel.

**Stage 3.** The entire junctional epithelium is on the cementum, and the base of the sulcus is at the cemento-enamel junction

**Stage 4.** The junctional epithelium has proliferated farther on the cementum. The base of the sulcus is on the cementum, a portion of which is exposed. Proliferation of the junctional epithelium on to the root is accompanied by degeneration of gingival and periodontal ligament fibers and their detachment from the tooth.